


Immediate Placement of SDIs in the Maxillary Arch

Immediate Post-Extraction Placement



Steven T. Cutbirth, DDS

INTRODUCTION

Small-diameter (mini) implants (SDIs) have proven to be very predictable for the stabilization of removable full and partial dentures as well as in some selective fixed-restorative situations.¹⁻³ SDIs have historically been placed in edentulous ridges

only after extraction sites have healed, a process that normally takes 3 to 12 months. Two surgeries are necessary when SDI placement is delayed in extraction cases; ie, one for the extractions, alveoplasty, and possible bone grafting, and a second surgery for SDI placement. Additionally, if the buccal wall of the extraction site is thin, especially in the maxillary anterior region, significant facial bone loss may occur during the 3 to 12 months of healing, creating a knife-edged ridge. SDIs cannot be predictably placed in a knife-edged ridge without ridge modification (ie, flattening). The technique and advantages of immediate placement of SDIs at the time of maxillary anterior tooth extraction are discussed in this article. A brief history of SDIs is as follows:

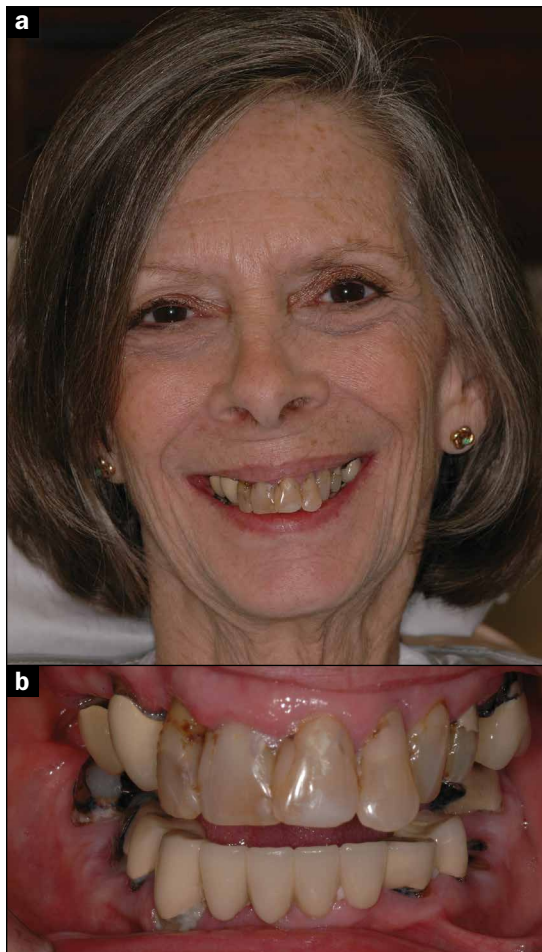
- In the 1970s, Victor Syndax first used small-diameter endodontic posts to stabilize dentures. His work led to the development of the mini dental implant (MDI) concept.

- In 1999, a 1.8-mm-diameter implant was launched globally by IMTEC Corporation for “ongoing use.” In 2002, IMTEC launched the 2.4-mm diameter implant for use in softer maxillary bone.

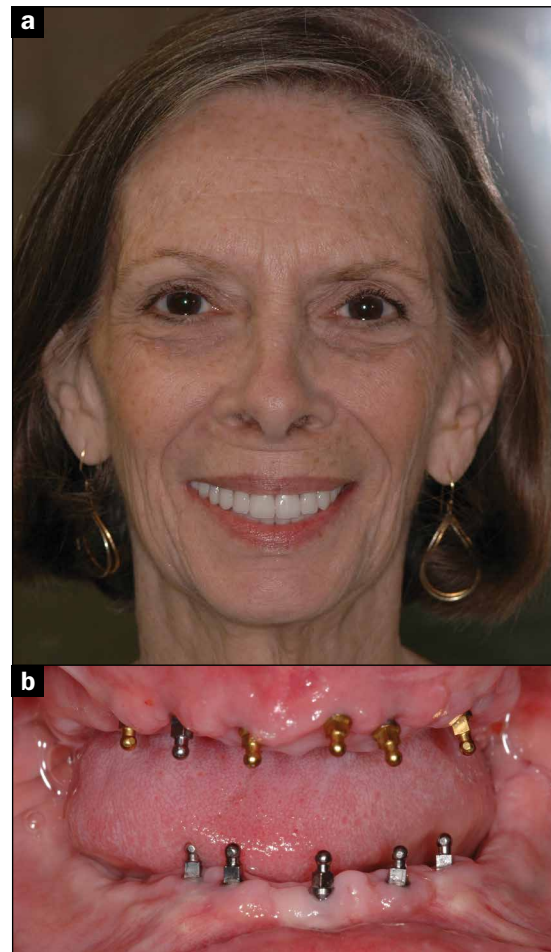
- In 2003, MDIs were indicated for long-term use. The success rate of SDIs was approximately 83% in the maxillary arch and 95% in the mandibular arch, comparable to root-form implants.

- The first of the baby boomers turned 65 years of age in 2011. More than 35 million adults in the United States (approximately 20%) were edentulous;^{4,5} 90% of denture patients were unhappy with the fit of their dentures.

There is a clear, unmet patient need for removable full-denture and partial-denture stabilization; SDIs offer an excellent option for this stabilization at a lower cost and with easier placement and replacement than root-form implants. Our



Before Image. The patient presented with hopeless teeth requiring extraction.



After Image. The final maxillary and mandibular dentures. The patient was very pleased with the final result.

ongoing objectives are to expand SDI utilization, simplify procedures, and minimize the number of surgeries required. SDI utilization and predictability can be improved and expanded significantly through ridge-modification procedures, such as turning knife-edged ridges into flat ridges that are receptive to implants.

Initial interest in SDIs involved placing them into unaltered mandibular edentulous ridges. Unfortunately, many mandibular edentulous ridges are not receptive to MDIs or root-form implants because the post-extraction ridge has healed into a knife-edged form. This may be due to resorption or to the buccal plate being lost during tooth extraction. Just as a “wood screw” cannot be predictably placed into a knife-edged wall surface, SDIs must be inserted into a flat alveolar crest so that the threads of the implant are surrounded

by at least 1.0 mm of bone and the implant is predictably received. In knife-edged mandibular ridge cases, the only way to attain this flat alveolar crest anatomy is by flap reflection and alveoplasty. Mandibular ridge modification has been described in previous articles by the author and will not be discussed here.⁶

Immediate SDI Placement in the Maxillary Arch Following Tooth Extraction

Immediate placement of SDIs in the maxillary arch post-extraction is a good idea for the following several reasons:

- If the teeth are extracted vertically, most of the buccal plate should remain intact.

- As with immediate placement of root-form implants following single-rooted tooth

continued on page 82

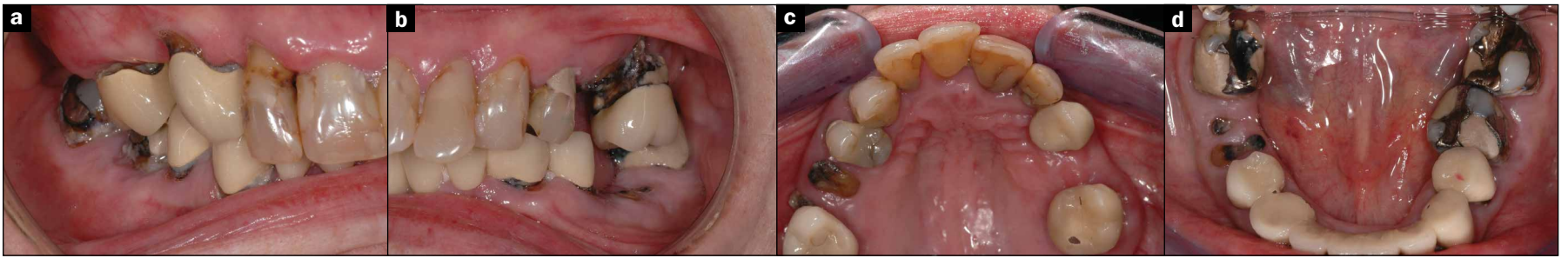


Figure 1. Preoperative photos of the hopeless teeth in the maxilla and mandible.

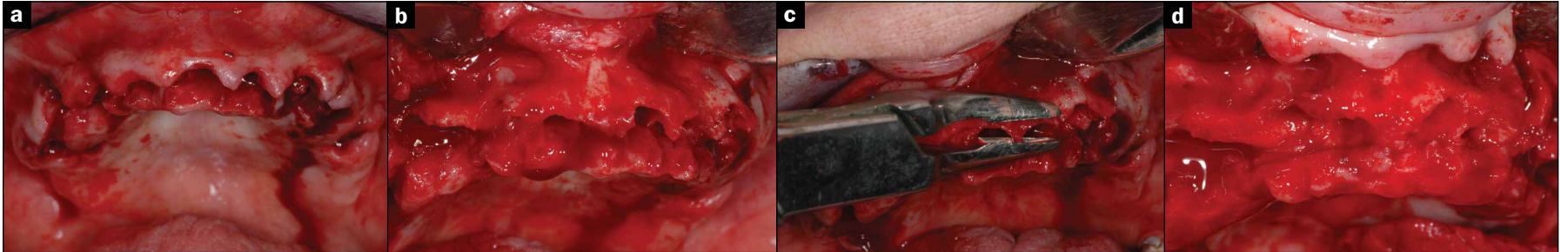


Figure 2. The patient had a protruding upper lip. The bony prominence was corrected with alveoplasty following maxillary gingival flap reflection.




Figure 3. An endodontic rubber stop was placed on the pilot drill (Aseptico) at the determined depth of each implant.

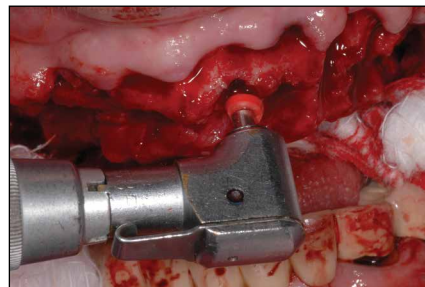


Figure 4. The tip of the pilot drill with rubber stop should be angled palatally.

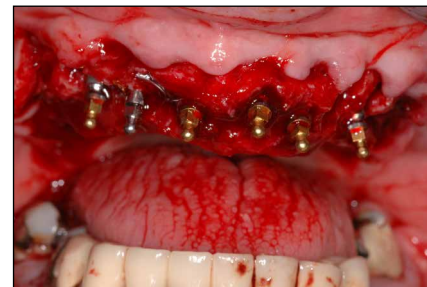

Figure 5. Each small-diameter implant (3M) was screwed into place in the osteotomies until all threads on the implants extended apically 1.0 mm past the alveolar crest rims.

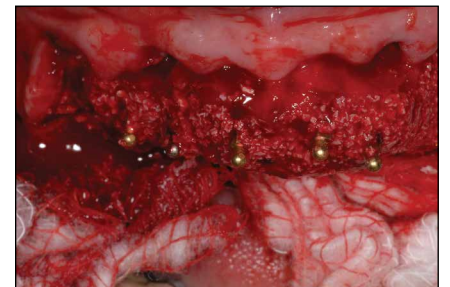

Figure 6. Bone graft material covers all threads of the implants.

Immediate Placement of...

continued from page 80

extraction, most of the time, the socket guides the surgeon into the ideal implant angulation; ie, the same angle as that of the extracted tooth. The SDI should normally be placed toward the *palatal* side of the socket.

- The bone at the apex of the extracted tooth is usually quite hard and offers an excellent implant seat/stabilization at or near 35 Ncm. The SDI osteotomy and final SDI placement should extend 3 to 5 mm apical to the tooth socket, ensuring initial SDI stability.

- When using 2.4-mm to 2.9-mm SDIs, most of the extracted tooth socket space is filled by the implant. The remaining void around the implant can be easily filled with small-diameter bone graft material covered with a resorbable collagen membrane. Platelet-rich fibrin (PRF) membranes are also being used to enhance and expedite healing. The bone-grafted socket heals into dense bone, surrounding the implant in 3 to 6 months.

- The patient does not have to undergo a second SDI placement surgery following extraction site healing.

CASE REPORT

Diagnosis and Treatment Planning

A 65-year-old female presented with teeth requiring extractions (Before Image and Figure 1). She had smoked at least one pack of cigarettes per day for more than 40 years; however, her overall health appeared to be good and unremarkable. Even though her teeth were unattractive, she was very concerned about her appearance and had heard horror stories about the appearance and function of dentures without implant support.

Following a comprehensive dental examination, it was determined that her remaining teeth were hopeless and should be extracted. All-on-4 fixed hybrid dentures as well as removable dentures supported by root-form implants or SDIs were discussed in detail with the patient at the consultation appointment; the accompanying case photographs were reviewed. The patient elected to go with SDIs and removable dentures, understanding that she had to stop smoking. Smoking and severe bruxism and/or daytime clenching are 2 serious contraindications to implant osseointegration and longevity. The patient lived several

hours away and was employed, so she wished to have the fewest appointments possible without compromising the final result.

At the examination appointment, impressions were taken of the maxillary and mandibular teeth for fabrication of an immediate maxillary denture. An arbitrary face-bow record was taken for mounting of the stone models on a semi-adjustable articulator (Denar Mark II Articulator [Whip Mix]). The maxillary immediate denture was fabricated from these mounted models. A mandibular denture would not be fabricated until the mandibular implants had osseointegrated with the bone grafted extraction sockets 3 months post-insertion.⁷ The final denture can then be produced. During those 3 months without a mandibular denture or mandibular teeth, the patient can function well with minimal compromise related to diet (soft diet recommended) or appearance.

Treatment Appointment

The patient was monitored and sedated, and all the remaining maxillary and mandibular teeth were extracted. SDI placement was accomplished in the

mandibular arch as described by the author in a previous article in *Dentistry Today*.⁷ Preoperatively, the patient had a very pronounced protruding upper lip. That bony prominence was corrected with alveoplasty following maxillary gingival flap reflection (Figure 2), creating a pleasing final result. Whenever possible, it is desirable to reflect the gingival flaps minimally to preserve optimal blood supply to the healing area. Studies have shown there is less bone loss following tooth extraction with minimal flap reflection. If minimal or no alveoplasty is required, optimal flap reflection following tooth extraction and SDI or root-form implant placement is just apical to the alveolar crest. This allows the surgeon to view the alveolar crests of each extraction site. It also allows for implant placement at the optimal depth and lateral positions while preserving gingival blood supply to the existing and healing bone, which allows minimal vertical bone resorption during healing. In this case, significant buccal plate alveoplasty was required, necessitating more aggressive flap reflection.

The sockets of the maxillary anterior teeth were 9.0 to 11.0 mm deep from the

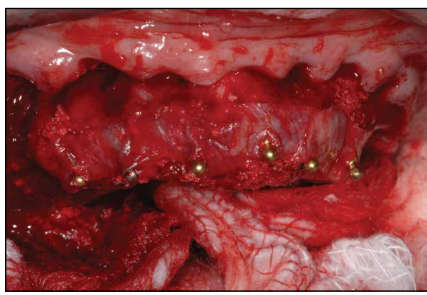


Figure 7. Resorbable collagen membranes (DynaMatrix) were used.

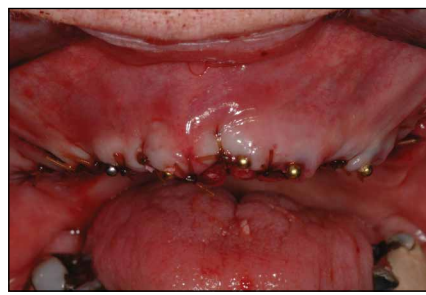

Figure 8. Reflected full-thickness gingival flaps were sutured with 3-0 chromic gut.

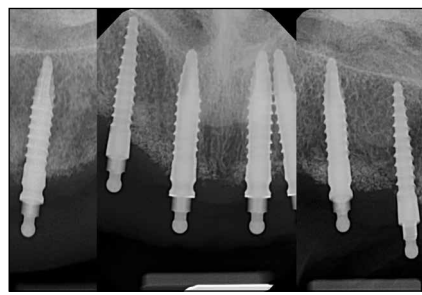


Figure 9. Three months post-surgery, the clinical presentation with radiographs demonstrating osseointegration and bone healing.

alveolar crests to the apices of the sockets when measured with a periodontal probe. The SDI osteotomies created with the pilot drill (Aseptic) extended approximately 5.0 mm apical to the apices of the sockets. An endodontic rubber stop was placed on the pilot drill at the determined depth of each implant (Figure 3). With high water-volume irrigation, the pilot drill osteotomies were placed with the drill situated along the palatal side of the extraction sites. It is important that the coronal (ball) part of the implant does not protrude facially through the denture and the apical tip of the implant does not protrude facially through the buccal plate of bone. This ideal placement is accomplished if pressure is placed on the palatal aspect of the maxillary extraction socket with the entire length of the pilot drill. The tip of the pilot drill is angled slightly palatally (Figure 4).

Each 2.9-mm SDI (3M) was screwed into place in the osteotomies with the finger driver and then the winged thumb wrench (3M) until all threads on the implants extended apically 1.0 mm past the alveolar crest rims (Figure 5). This allows for the implant threads to remain covered with bone even after a small amount of anticipated bone resorption takes place during socket healing. A 2.0-mm diameter pilot drill may be necessary when utilizing 2.9-mm SDIs because the bone at the apices of the maxillary sockets can be quite dense, similar to type 1 or 2 mandibular bone, and a small pilot drill osteotomy may not be adequate to accept the larger SDIs. For excellent osseointegration to occur, it is not essential that 35 Ncm of torque be achieved at immediate SDI placement in the maxillae. It is, however, essential that the SDIs cannot be advanced with the finger driver any further once terminal implant depth is reached. Osseointegration success is predictably high if the winged wrench or torque wrench is required for SDI advancement past the desired terminal implant depth.

Once all SDIs are placed and stable, freeze-dried cancellous bone allograft (Geistlich Bio-Oss) 0.5 mm to 1.0 mm

It is important to minimize lateral forces on the SDIs, especially during the first 3 months of osseointegration.

in diameter is placed around the SDIs in the extraction sockets. All threads of the implants are covered with bone graft material (Figure 6). The bone graft may then be covered with PRF and/or resorbable collagen membranes. In this case, only resorbable collagen membranes (DynaMatrix) were used (Figure 7). The reflected full-thickness gingival flaps were then sutured with 3-0 chromic gut suture (Figure 8). Chromic gut resorbs in approximately 2 weeks. It is important that the flaps are closed with minimal suture pressure on the tissue. If there is suture pressure significant enough to cause tissue blanching, there is a good chance the suture will pull through the tissue and the flaps will open. This problem will not cause implant or bone graft loss, but the open flaps will need to be resutured as soon as possible. Checking the surgical sites within one week is suggested in case a portion of the flap has pulled loose and opened. Flap opening following suturing is less likely if a deep “bite” is taken in each flap with the suture needle. As previously stated, there is minimal suture pressure pulling the tissue (there should be no tissue blanching), and the suturing is accomplished in attached, keratinized gingiva. If there is no or minimal attached keratinized gingiva surrounding the implants, gingival grafting should ideally be performed prior to implant placement to facilitate both suturing and long-term implant survival. Additionally, if there is inadequate keratinized gingiva surrounding the SDIs, there is a high probability the nonkeratinized gingiva around the implants will become sore and inflamed once the denture is placed. Nonkeratinized gingival tissue is not designed to withstand the pressure and slight rubbing of removable full or partial dentures.

As previously stated, the patient would wear an immediate denture for 3

months in the maxilla only; because of tissue reflection and healing, there is no place to “rest” the mandibular denture on the tissue. The maxillary immediate denture is supported only by the palatal and posterior ridge tissue, as the maxillary SDIs do not secure the immediate denture. Green rubber shims are placed on the balls and necks of the SDIs; then, the maxillary immediate denture is relined with a soft liner (SECURE Soft [3M]). The green rubber shims are picked up and held by the soft liner in the maxillary immediate denture. It is easier for the patient to orient the immediate denture and place it into the mouth correctly with the green rubber shims sliding onto the SDI balls. Additionally, the rubber shims, along with the soft liner and no opposing teeth or denture, place minimal lateral pressure on the SDIs during the 3 months of healing and osseointegration. Lateral biting/clenching stress on the SDIs during healing is a major cause of osseointegration failure.

Following 3 months of osseointegration and bone healing (Figure 9), the final maxillary and mandibular dentures may be fabricated (After Image); this process will not be discussed in this article.

IN SUMMARY

Placement of SDIs at the time of tooth extraction is a predictable and recommended procedure, if the technique is understood and followed precisely. The reasons for immediate placement are as follows: only one surgery for the patient; if the teeth are carefully extracted vertically, the buccal plate can be preserved and supported by the bone graft and SDIs; the extracted tooth sockets are normally precise guides for SDI placement; and the bone at the apices of the maxillary tooth sockets is dense, offering excellent stabilization of the immediately placed SDIs.

It is important that the SDIs are placed as far palatally in the extraction sockets as possible, with the tip of the pilot drill and SDIs angled slightly toward the palatal. If alveoplasty and significant flap reflection is required, 1.0 mm to 2.0 mm of vertical alveolar crest resorption should be anticipated during placement. The SDIs should extend approximately 5.0 mm apical to the apices of the extraction sockets to attain initial stabilization at or near 35 Ncm torque pressure. Once the SDIs are in place, allograft bone is placed in any voids surrounding the implants, then covered by PRF and/or resorbable collagen membranes. The greater the surface area of the SDI, the better; consequently, the larger the SDI, the better: 2.9-mm x 13- to 15-mm SDIs are ideal.

It is important to minimize lateral forces on the SDIs, especially during the first 3 months of osseointegration. Only a soft-lined maxillary immediate denture is placed, with no lower denture during the 3 months of SDI osseointegration and tissue healing. Patients do well with only the maxillary immediate denture. Eating and aesthetics are not a significant problem. It is important that the SDIs osseointegrate with minimal lateral forces for 3 months, then final dentures may be fabricated and secured by the SDIs.♦

References

1. Sohrabi K, Mushantat A, Esfandiari S, et al. How successful are small-diameter implants? A literature review. *Clin Oral Implants Res.* 2012;23:515-525.
2. Bulard RA, Vance JB. Multi-clinic evaluation using mini-dental implants for long-term denture stabilization: a preliminary biometric evaluation. *Compend Contin Educ Dent.* 2005;26:892-897.
3. Shatkin TE, Shatkin S, Oppenheimer BD, et al. Mini dental implants for long-term fixed and removable prosthetics: a retrospective analysis of 2514 implants placed over a five-year period. *Compend Contin Educ Dent.* 2007;28:92-99.
4. American College of Prosthodontists. GoToAPro. Facts & Figures: Dentures. gotoapro.org/news/facts-figures. Accessed February 16, 2016.
5. Christensen GJ. Ask Dr. Christensen. *Dent Econ.* 2011;101:54.
6. Cutbirth ST. Improving existing dentures with mini implants: idealizing a knife-edged mandibular ridge. *Dent Today.* 2013;32:100-105.
7. Cutbirth ST. Immediate mini implant placement following extractions. *Dent Today.* 2014;33:100-105.

Dr. Cutbirth graduated from Baylor Dental College in 1979, then completed a 2-year fellowship there and became a member of the teaching faculty at the Pankey Institute in Florida for 20 years. He currently practices restorative dentistry in Waco, Tex (wacosedationdentist.com) and is director of the Center for Aesthetic Restorative Dentistry (centerforard.com), located in Dallas, a hands-on restorative teaching center for practicing dentists. He has lectured and published extensively on the topics of (1) systematic restoration of the severely worn dentition with vertical dimension increase, (2) diagnosis and treatment of occlusal problems and facial pain, (3) complex aesthetic restorative dentistry, (4) ridge modification and bone grafting for small-diameter implant utilization, and (5) the most effective and productive dental practice systems. He can be reached at (254) 772-5420 or at card1611@gmail.com.

Disclosure: Dr. Cutbirth reports no disclosures.